NIH Public Access
Author Manuscript
Respir Care. Author manuscript; available in PMC 2015 July 01.

Published in final edited form as:
Respir Care. 2014 July ; 59(7): e98–e102. doi:10.4187/respcare.02513.

Teaching case of the month: Acute upper airway obstruction by a lingual thyroglossal duct cyst and implications for advanced airway management

Kanecia O. Zimmerman, MD, MPH[1], **Susan Hupp, MD**[1], **Ali Bourguet-Vincent, MD**[2], **Erin Bressler, MD**[2], **Eileen Raynor, MD**[3], **David A. Turner, MD**[1], and **Kyle J. Rehder, MD**[1]

[1]Division of Pediatric Critical Care Medicine, Department of Pediatrics, Duke Children's Hospital, Durham, North Carolina

[2]Department of Pediatrics, Duke Children's Hospital, Durham, North Carolina

[3]Division of Otolaryngology, Department of Pediatric Surgery, Duke Children's Hospital, Durham, North Carolina

Keywords

thyroglossal duct cyst; airway obstruction; difficult airway; intubation; neonatal; respiratory failure; respiratory distress

Introduction

Respiratory failure in infants and children is a common cause of intensive care unit (ICU) admission, and diseases that jeopardize the airway are the most frequent cause of cardiac arrest in neonatal and pediatric patients.[1, 2] In neonates specifically, there are numerous causes for respiratory distress, with upper airway obstruction being an important source of morbidity and mortality in this population.[3, 4] This case will discuss the diagnosis and management of acute upper airway obstruction and subsequent difficult airway management in a previously well neonate.

Case summary

An eighteen day old term infant with an unremarkable perinatal and birth history presented to the Emergency Department (ED) with acute onset, severe respiratory distress.

Prior to presentation, the patient had no evidence of fever, fussiness, or congestion. Family members reported a nonproductive cough and intermittent noisy breathing since birth, with increased noisiness during feeding. On presentation, the patient was noted to be tachypneic

Corresponding Author: Kanecia O. Zimmerman, MD, MPH, Division of Pediatric Critical Care, DUMC Box 3046, Durham, NC 27710, kanecia.obie@dm.duke.edu.

Disclosures: None

Site of Case: Duke University Medical Center; Durham, NC, USA
HIPPA approval obtained for case

NIH-PA Author Manuscript
NIH-PA Author Manuscript
NIH-PA Author Manuscript

NIH-PA Author Manuscript

NIH-PA Author Manuscript

NIH-PA Author Manuscript

with respiratory rates in the 70s, significant sternal retractions, nasal flaring, and oxygen desaturations. Lung exam revealed poor aeration bilaterally, but perfusion was adequate.

Due to impending respiratory failure, providers emergently initiated modified rapid sequence intubation using atropine for premedication, etomidate for sedation, and insuring ability to bag mask ventilate prior to paralysis with rocuronium. Vocal cords were not visualized on the initial intubation attempt. The infant was bag mask ventilated and oxygen saturations were maintained initially, but ventilation and oxygenation became progressively more difficult, with increased abdominal distension and worsening gas exchange. Progressive hypoxia led to a brief bradycardic arrest during continued attempts to establish an artificial airway, and patient received chest compressions, epinephrine, and atropine prior to restoration of adequate heart rate. During attempts, the emergency airway, pediatric anesthesia, and pediatric otolaryngology teams were called. Successful endotracheal intubation was achieved with a 2.5 mm uncuffed endotracheal tube on the tenth attempt, by the fifth provider, the pediatric otolaryngology attending. Hyperextension of the neck and cricoid pressure were required, and despite these manipulations, the airway was described as anteriorly displaced with a grade III view. Advanced airway devices such as a laryngeal mask airway or fiberoptic scope were not attempted during intubation. Upon intubation, gas exchange improved immediately, and the patient was transported to the Pediatric Intensive Care Unit (PICU) for further evaluation and management.

Initial examination in the PICU showed no facial dysmorphisms, adequate perfusion in all extremities, no cardiac murmur, and clear breath sounds bilaterally. Laboratory studies included an arterial blood gas with a pH of 7.38, $paCO_2$ of 32 mm Hg, and paO_2 324 mm Hg on FiO_2 of 1.0. There was no organ dysfunction as evidenced by normal liver enzymes, renal function tests, and lactate. Further evaluation included a normal chest radiograph, normal transthoracic echocardiogram, negative sepsis evaluation, and an electroencephalogram (EEG), which was obtained as a routine evaluation for hypoxic ischemic encephalopathy status post the patient's code event. The EEG demonstrated diffuse slowing consistent with nonspecific encephalopathy, likely secondary to medication effect.

Throughout his PICU course, the patient required minimal ventilatory support and had no evidence of lung disease as the etiology for his respiratory failure. Given concern for upper airway obstruction, the patient was evaluated in the operating room. Rigid bronchoscopy suggested the presence of a large tongue mass that displaced the airway and epiglottis anteriolaterally, but complete visualization and further characterization were not possible (Figure 1). Flexible bronchoscopy revealed similar findings, and magnetic resonance imaging (MRI) was then performed to better delineate the anatomic abnormality, presumed to be either a lingual thyroglossal duct cyst or lingual thyroid. MRI revealed a 1.0 cm × 1.1 cm × 1.2 cm nonenhancing mass at midline at the base of the tongue that displaced the endotracheal tube rightward. (Figure 2) Normally positioned thyroid tissue was noted, and the lesion was presumed to be a thyroglossal duct cyst.

The patient then underwent repeat direct laryngoscopy and marsupilization of the lesion, and pathology was consistent with thyroglossal duct cyst. He was subsequently extubated to nasal CPAP and quickly weaned to room air. Two days after extubation, he was transferred

NIH-PA Author Manuscript

NIH-PA Author Manuscript

NIH-PA Author Manuscript

to the general pediatrics ward for ongoing management and was ultimately discharged home without need for respiratory support.

Discussion

This report describes an infant with acute respiratory failure secondary to upper airway obstruction. Given the wide differential diagnosis for respiratory distress in neonates, upper airway obstruction is often not the first consideration as a potential etiology beyond the immediate newborn period.[5, 6] Infants with upper airway obstruction most commonly present with stridor, and while the differential diagnosis of airway obstruction is broad, the most likely etiology for upper airway obstruction in a previously health infant is laryngomalacia.[5] (Table 1)

In this case, airway obstruction was secondary to a lingual thyroglossal duct cyst. This lesion is an uncommon congenital anomaly, comprising only 0.6-3% of thyroglossal duct remnants, which occur in 700 of 10,000 births.[7] Lingual cystic remnants of the thyroglossal duct result from canalization of an epithelial remnant that connects the migrating thyroid gland to the foramen cecum of the tongue, leading to subsequent mucous production and resulting cyst formation.[8] Though rare, these anomalies may cause fixed or dynamic upper airway obstruction by a ball-valve mechanism between the cyst and the laryngeal inlet.[9]

As compared to other thyroglossal duct remnant diseases, which most commonly present as midline neck masses in the setting of superinfection,[3] lingual cysts may preclude routine identification due to their more obscure location. In a series reported by Bai et al., only one of nine cysts was identified by tongue spatula, with eight of nine cysts being identified by laryngoscopy.[10] However, identification with laryngoscope is not always possible. In addition, as in this case, preceding symptoms may be subtle and non-specific, including dysphonia[7] or mild feeding difficulties.[11] If unidentified, the presence of a lingual thyroglossal duct cyst causing upper airway obstruction may be associated with significant risk for mortality.[12, 13] Several case reports describe an infant death, initially presumed to be due to Sudden Infant Death Syndrome (SIDS), but subsequently thought attributable to large lingual thyroglossal duct cysts.[8, 14, 15] Thus, a high index of suspicion for this possible lesion is necessary in infants who present with signs and symptoms of upper airway obstruction.[16] If suspected, further work-up should include evaluation by a pediatric otolaryngologist and cross sectional imaging with either computed tomography (CT) or MRI.[3] Surgical intervention for a lingual thyroglossal duct cyst can be curative. However, prior to surgical intervention, one must confirm normal placement and functioning of thyroid tissue given the possibility of lingual thyroid presenting similarly on cross-sectional imaging. [7]

As indicated by this case, the etiology of upper airway obstruction may be obscure in an infant presenting with acute respiratory compromise. Thus, recognition of the potential for a difficult airway and need for advanced airway management are central to preventing potential morbidity and mortality. The American Society of Anesthesiologists ‘Practice guidelines for management of the difficult airway’ suggest that while “there is insufficient published evidence to evaluate the effect of a bedside medical history or predicting the

NIH-PA Author Manuscript

NIH-PA Author Manuscript

NIH-PA Author Manuscript

presence of a difficult airway…there is suggestive evidence that some features of a patient's medical history …may be related to the likelihood of encountering a difficult airway".[17] In addition to a suggestive history, [4, 11, 12] features of the physical examination could also be a clue to the possibility of a difficult airway.[17, 18] Among the suggestive historical clues include difficulty with feeding, stridor, respiratory distress of acute onset, positional change in work of breathing, and history of a difficult intubation. Physical examination features suggestive of a difficult airway include micrognathia, macroglossia, glossoptosis, short neck or limited range of motion, highly arched or narrowed palate, midface hypoplasia, and respiratory distress in the absence of adequate air entry. In the case of suggestive history or physical examination, practice guidelines suggest benefit from a preplanned strategy, consisting of early notification of a specialized airway team, refraining from paralysis until capacity to control ventilation is certain, and available alternatives to endotracheal intubation with rigid laryngoscopy (Figure 3).[17, 19]

Existing alternatives to endotracheal intubation with rigid laryngoscopy include various tools for fiberoptic-guided intubation and intubation via video laryngoscopy. These options improve the view of the larynx and may therefore minimize the trauma and risk for prolonged hypoventilation associated with repeated attempts at direct laryngoscopy. However, the use of these aids requires the adoption and maintenance of an additional skill set to manipulate the endotracheal tube through the vocal cords under indirect visualization.[19] Furthermore, these tools are often not readily available, and additional delay of adequate gas exchange may be avoided by placement of a laryngeal mask airway (LMA). LMAs are more readily available, easily placed, and may facilitate adequate gas exchange while awaiting specialist assistance for a more definitive airway in the setting of difficult intubation. In rare cases, such as in some airway lesions below the vocal cords,[19] an appropriately positioned LMA is ineffective in restoring ventilation and a surgical airway may be required.[20] Most commonly, this surgical airway is placed by trained personnel via needle crycothyroidotomy.[21] Alternatively, extracorporeal membrane oxygenation (ECMO) may be needed as a bridge to definitive surgical intervention in neonates, infants, and children with significant upper airway obstruction in whom an artificial airway cannot be established.[22, 23]

This case demonstrates that awareness and planning are important for all patients with acute respiratory distress given the potential risk for a difficult airway, even when there are no clear historical or physical examination features that would be suggestive. Evidence suggests that the incidence of a difficult airway is 1-18% in adults[24-26] and may be as high as 15% in neonatal and pediatric patients.[27,28] Additionally, adult and pediatric studies have described significant morbidity and mortality associated with advanced airway management, with adverse events occurring in 14-47% of intubations.[25, 29, 30] While respiratory distress is a common presentation in neonates,[6, 31] practitioners should be vigilant in considering a broad differential diagnosis, including uncommon diagnoses such as upper airway obstruction. In the event that advanced airway support is necessary, appropriate recognition and preparation for a difficult intubation may prevent significant morbidity and mortality for patients with acute respiratory failure.

NIH-PA Author Manuscript NIH-PA Author Manuscript NIH-PA Author Manuscript

Acknowledgments

Funding: Dr Zimmerman receives research support from the National Institute of General Medical Sciences (5T32GM086330-03 [PIs: Brouwer, Benjamin, Watkins]).

References

1. Jardine, D.; Bhutta, OJ.; Inglis, A. Specific diseases of the respiratory system: upper airway. In: Fuhrman, BP.; Zimmerman, JJ., editors. Pediatric Critical Care. 4. Philadelphia, PA: Elsevier; 2011. p. 561-574.
2. Young KD, Seidel JS. Pediatric cardiopulmonary resuscitation: a collective review. Ann Emerg Med. 1999; 33(2):195–205. [PubMed: 9922416]
3. Laya BF, Lee EY. Congenital causes of upper airway obstruction in pediatric patients: updated imaging techniques and review of imaging findings. Semin Roentgenol. 2012; 47(2):147–158. [PubMed: 22370193]
4. Sasidaran K, Bansal A, Singhi S. Acute upper airway obstruction. Indian J Pediatr. 2011; 78(10): 1256–1261. [PubMed: 21559808]
5. Kier C, Balluz R, Modi V, Chandran L. Visual diagnosis: respiratory distress: a great masquerader. Pediatr Rev. 2011; 32(10):e95–101. [PubMed: 21965715]
6. Warren JB, Anderson JM. Newborn respiratory disorders. Pediatr Rev. 2010; 31(12):487–495. quiz 496. [PubMed: 21123510]
7. Sameer KS, Mohanty S, Correa MM, Das K. Lingual thyroglossal duct cysts--a review. Int J Pediatr Otorhinolaryngol. 2012; 76(2):165–168. [PubMed: 22192899]
8. Byard RW, Bourne AJ, Silver MM. The association of lingual thyroglossal duct remnants with sudden death in infancy. Int J Pediatr Otorhinolaryngol. 1990; 20(2):107–112. [PubMed: 2286503]
9. Weldon BC, Krafcik JM. Breath-holding—like spells in an infant: An unusual presentation of lingual thyroglossal duct cyst. Journal of Pediatric Surgery. 2000; 35(9):1381–1384. [PubMed: 10999707]
10. Bai W, Ji W, Wang L, Song Y. Diagnosis and treatment of lingual thyroglossal duct cyst in newborns. Pediatr Int. 2009; 51(4):552–554. [PubMed: 19438825]
11. Miller CK. The implications of upper-airway obstruction on successful infant feeding. Seminars in speech and language. 2007; 28(3):180. [PubMed: 17647130]
12. Eom M, K YS. Asphyxiating Death Due to Basal Lingual Cyst (Thyroglossal Duct Cyst) in Two-Month-Old Infant is Potentially Aggravated After Central Catheterization with Forced Positional Changes. The American Journal of Forensic Medicine and Pathology. 2008; 29(3)
13. Sauvageau A, Belley-Côté ÉP, Racette S. Fatal asphyxia by a thyroglossal duct cyst in an adult. Journal of Clinical Forensic Medicine. 2006; 13(6–8):349–352. [PubMed: 17027318]
14. Kanawaku. Sudden Infant Death: lingual thyroglossal duct cyst versus environmental factors. Forensic Science Int. 2006; 156(2-3):158–160.
15. Hanzlick R. Lingual thyroglossal duct cyst causing death in a four-week old infant. Journal of Forensic Sciences. 1984; 29(1):345. [PubMed: 6699603]
16. Paez P, Warren WS, Srouji MN. Stridor as the Presenting Symptom of Lingual Thyroglossal Duct Cyst in an Infant. Clinical Pediatrics. 1974; 13(12):1077–1078. [PubMed: 4434667]
17. Practice guidelines for management of the difficult airway: an updated report by the American Society of Anesthesiologists Task Force on Management of the Difficult Airway. Anesthesiology. 2003; 98(5):1269–1277. [PubMed: 12717151]
18. Infosino A. Pediatric upper airway and congenital anomalies. Anesthesiol Clin North America. 2002; 20(4):747–766. [PubMed: 12512261]
19. Sims C, von Ungern-Sternberg BS. The normal and the challenging pediatric airway. Paediatr Anaesth. 2012; 22(6):521–526. [PubMed: 22594404]
20. Heard AM, Green RJ, Eakins P. The formulation and introduction of a ‘can’t intubate, can’t ventilate’ algorithm into clinical practice. Anaesthesia. 2009; 64(6):601–608. [PubMed: 19453312]

NIH-PA Author Manuscript NIH-PA Author Manuscript NIH-PA Author Manuscript

21. Cote CJ, Hartnick CJ. Pediatric transtracheal and cricothyrotomy airway devices for emergency use: which are appropriate for infants and children? Paediatr Anaesth. 2009; 19(Suppl 1):66–76. [PubMed: 19572846]
22. Goldman AP, Macrae DJ, Tasker RC, Edberg KE, Mellgren G, Herberhold C, et al. Extracorporeal membrane oxygenation as a bridge to definitive tracheal surgery in children. J Pediatr. 1996; 128(3):386–388. [PubMed: 8774512]
23. Huang SC, Wu ET, Chi NH, Chiu SN, Huang PM, Chen YS, et al. Perioperative extracorporeal membrane oxygenation support for critical pediatric airway surgery. Eur J Pediatr. 2007; 166(11): 1129–1133. [PubMed: 17205242]
24. Ovassapian A, Glassenberg R, Randel GI, Klock A, Mesnick PS, Klafta JM. The unexpected difficult airway and lingual tonsil hyperplasia: a case series and a review of the literature. Anesthesiology. 2002; 97(1):124–132. [PubMed: 12131113]
25. Egan TD, Wong KC. Predicting difficult laryngoscopy for tracheal intubation: an approach to airway assessment. Ma Zui Xue Za Zhi. 1993; 31(3):165–178. [PubMed: 7968338]
26. Deller A. [Incidence and predictability of difficult intubation]. Inzidenz und Vorhersehbarkeit der schwierigen Intubation. Anasthesiol Intensivmed Notfallmed Schmerzther. 1995; 30(3):169–171. [PubMed: 7605837]
27. Nishisaki A, Ferry S, Colborn S, DeFalco C, Dominguez T, Brown CA 3rd, et al. Characterization of tracheal intubation process of care and safety outcomes in a tertiary pediatric intensive care unit. Pediatr Crit Care Med. 2012; 13(1):e5–10. [PubMed: 21057359]
28. Blanco G, Melman E, Cuairan V, Moyao D, Ortiz-Monasterio F. Fibreoptic nasal intubation in children with anticipated and unanticipated difficult intubation. Paediatric anaesthesia. 2001; 11(1):49–53. [PubMed: 11123731]
29. Cook TM, Woodall N, Harper J, Benger J. Major complications of airway management in the UK: results of the Fourth National Audit Project of the Royal College of Anaesthetists and the Difficult Airway Society. Part 2: intensive care and emergency departments. Br J Anaesth. 2011; 106(5): 632–642. [PubMed: 21447489]
30. Gausche M, Lewis RJ, Stratton SJ, Haynes BE, Gunter CS, Goodrich SM, et al. Effect of out-of-hospital pediatric endotracheal intubation on survival and neurological outcome: a controlled clinical trial. JAMA. 2000; 283(6):783–790. [PubMed: 10683058]
31. Nitu ME, Eigen H. Respiratory failure. Pediatr Rev. 2009; 30(12):470–477. quiz 478. [PubMed: 19952128]
32. American Society of Anesthesiologists Task Force on Management of the Difficult Airway. Practice Guidelines for management of the difficult airway: an updated report by the American Society of Anesthesiologists Task Force on Management of the Difficult Airway. Anesthesiology. May; 2003 98(5):1269–77. [PubMed: 12717151]

NIH-PA Author Manuscript

NIH-PA Author Manuscript

NIH-PA Author Manuscript

Teaching points

- In the setting of a difficult airway, repeated attempts at intubation may lead to the inability to ventilate. Early use of a laryngeal mask airway and/or more advanced visual aids (fiberoptic bronchoscopy, video laryngoscopy) may restore ventilation and be lifesaving.
- Lingual thyroglossal duct cysts are an uncommon cause of neonatal upper respiratory obstruction, and require a high index of suspicion for appropriate diagnosis. Upper airway obstruction should be considered in the differential diagnosis of neonatal respiratory distress.

NIH-PA Author Manuscript

NIH-PA Author Manuscript

NIH-PA Author Manuscript

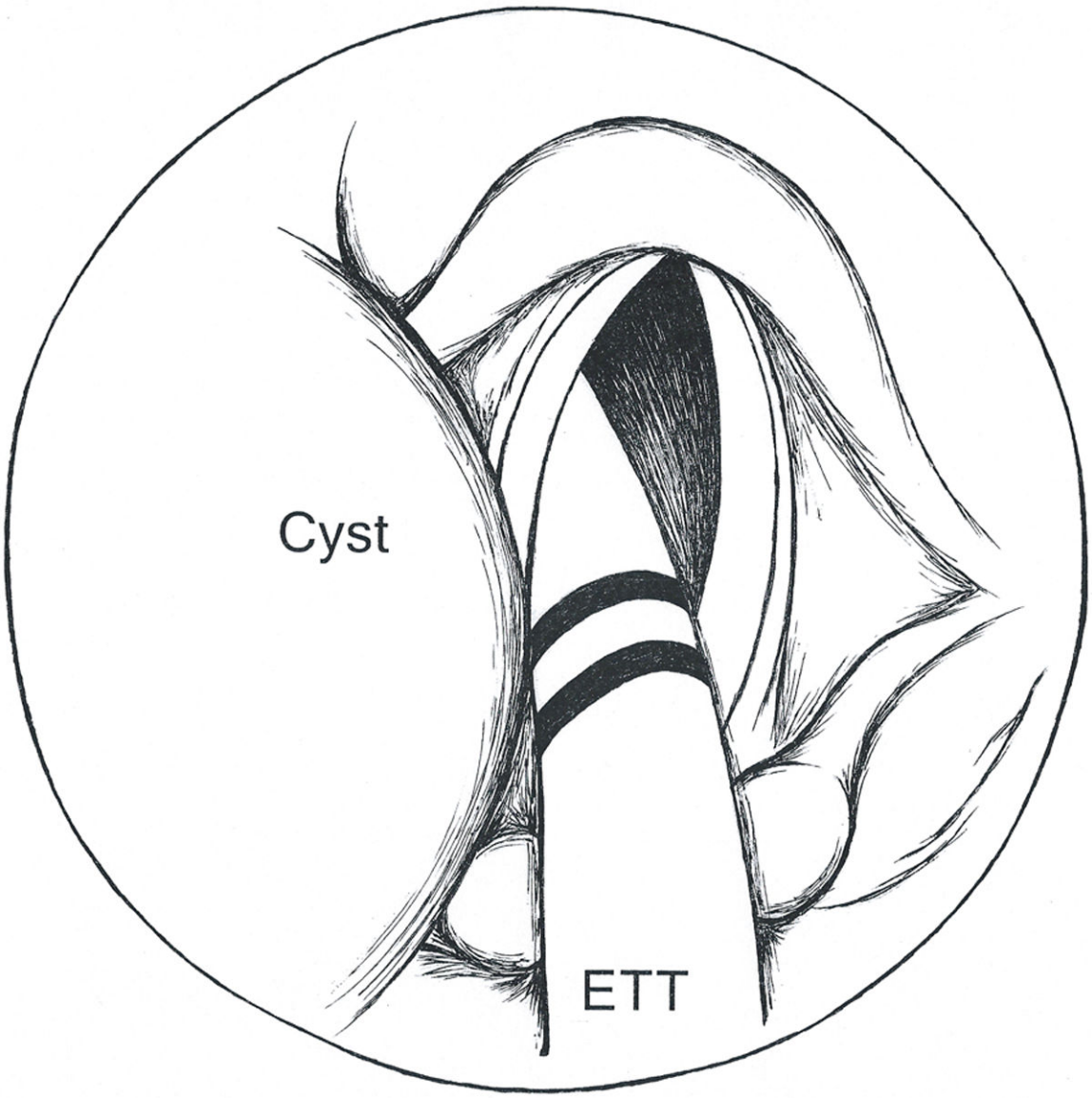

Figure 1.

Schematic of rigid bronchoscopy indicating anterolateral displacement of the airway and epiglottis to the right of the image by apparent tongue mass. Large tongue mass shown at the left of the image at approximately 9 o'clock.

NIH-PA Author Manuscript

NIH-PA Author Manuscript

NIH-PA Author Manuscript

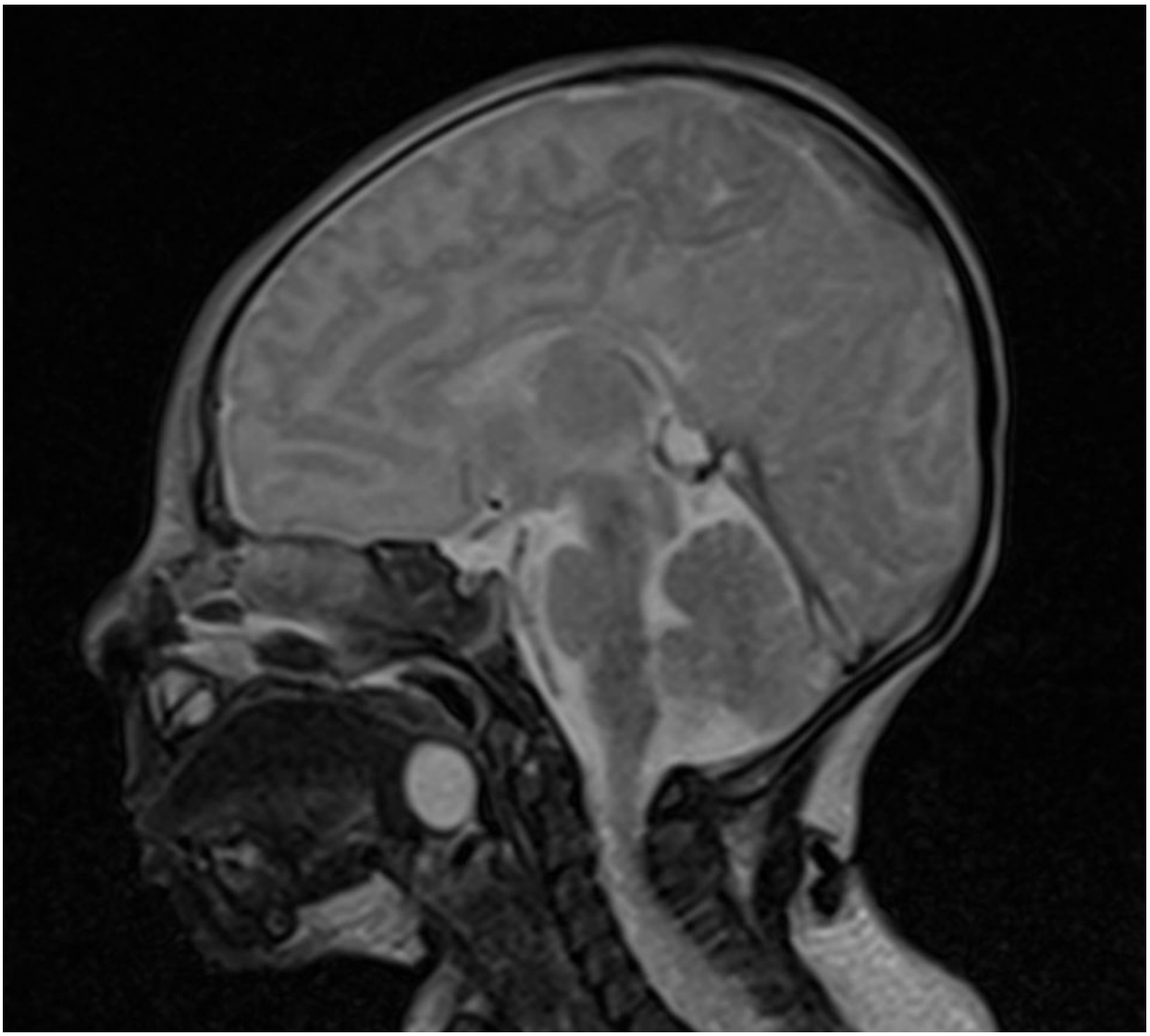

Figure 2.

MRI images demonstrate a 1.0 cm AP × 1.1 cm ML × 1.2 cm CC T2 hyperintense, nonenhancing mass at midline at the base of the tongue.

NIH-PA Author Manuscript

NIH-PA Author Manuscript

NIH-PA Author Manuscript

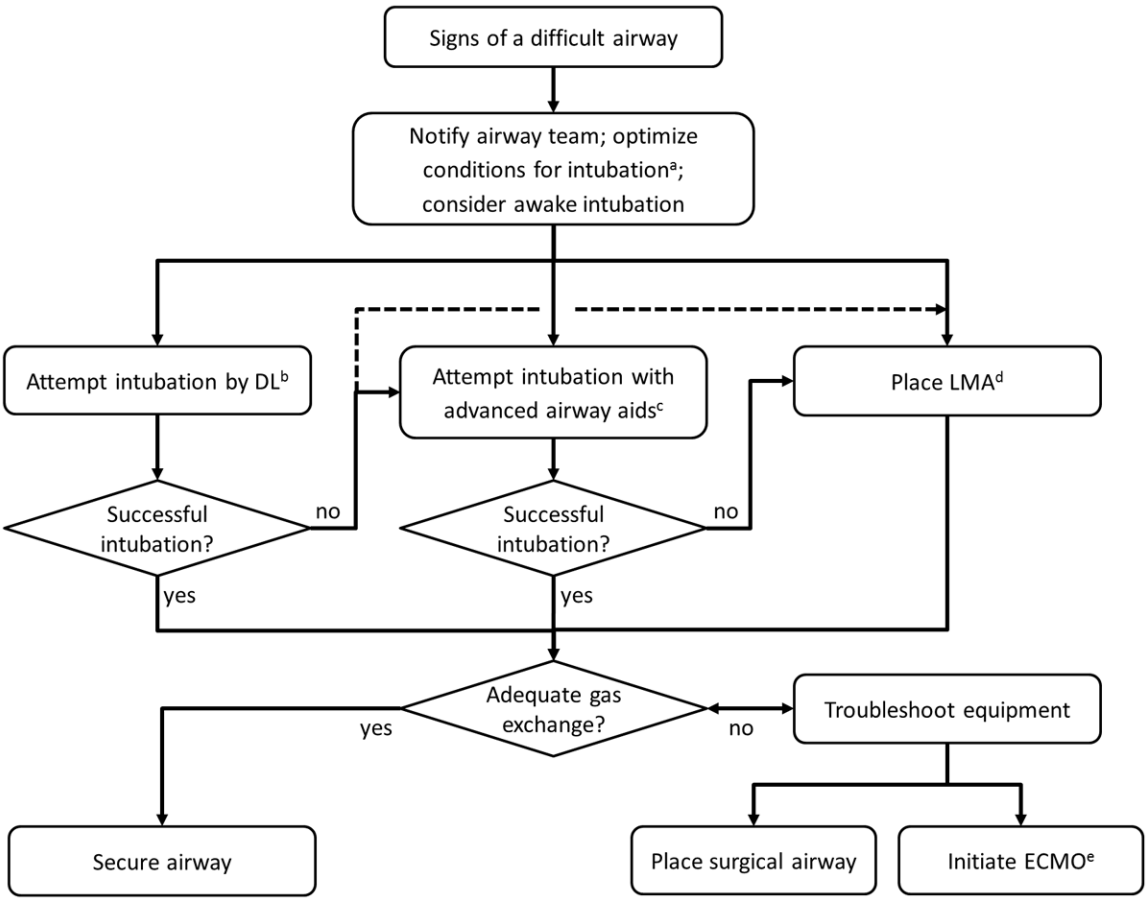

Figure 3.

Algorithm for management of a difficult airway

*see also: American Society of Anesthesiologists Difficult Airway Algorithm [ref #32]

[a]optimal conditions include adequate positioning, availability of an oral airway and a variety of laryngoscope blades and ETT sizes, and the presence of the most experienced provider; [b]DL = direct laryngoscopy; [c]advanced aids include fiberoptic bronchoscope or video laryngoscopy; [d]LMA = laryngeal mask airway; [e]ECMO = extracorporeal membrane oxygenation

NIH-PA Author Manuscript

NIH-PA Author Manuscript

NIH-PA Author Manuscript

Table 1

Potential causes of upper airway obstruction by typical age

Neonates and Infants (0-12 months of age)	**Toddlers and Pre-School Age (1-5 years of age)**
Choanal atresia/stenosis	Tonsillar and adenoid enlargement
Laryngomalacia/tracheomalacia/stenosis	Croup
Vascular ring/sling	Bacterial tracheitis
Airway masses (e.g. vascular malformations, papillomas, cysts)	Retropharyngeal abscess
Tracheal/laryngeal webs	Foreign body